

Anti-Müllerian hormone levels before and after uterine artery embolization

Bruce McLucas^a, William D. Voorhees III^b and Scott A. Snyder^c

^aDepartment of Obstetrics and Gynecology, University of California at Los Angeles, David Geffen School of Medicine, Los Angeles, CA, USA; ^bMed Institute Inc, West Lafayette, IN, USA; ^cCOOK[®] Research, Inc., West Lafayette, IN, USA

ABSTRACT

Objective: To determine the effects of uterine artery embolization (UAE) on ovarian reserve as measured by Anti-Müllerian hormone (AMH) levels.

Material and methods: Non-randomized, observational study of 89 women 23–40 years of age who received UAE. Control hormone levels were measured prior to UAE and the first post-embolization measurement was taken at various times post-procedure (mean = 190 ± 229 days).

Results: Historical work verified by our earlier work has shown that AMH levels decline with age. Regression analysis allows us to determine whether UAE contributes to a greater decline in AMH values over that naturally occurring with aging. The effect of the procedure was found to contribute no deleterious effect to the natural decline in AMH levels. In addition, multiple blood draws were obtained from 32 patients up to 47 months post-UAE. Regression studies with these patients as their own controls showed no long-term diminishment of ovarian reserve due to the UAE procedure.

Conclusions: Earlier reported data are consistent with larger sample size. UAE does not affect ovarian reserve in women <40 as evidenced by no significant change in AMH levels after embolization. Women who are of reproductive age and have uterine fibroids can consider UAE without concern for adverse effects on their fertility.

ARTICLE HISTORY

Received 3 May 2017
Accepted 14 July 2017

KEYWORDS

Anti-Müllerian hormone;
fertility; embolization;
uterine artery embolization

Introduction

Some authors have suggested that UAE causes diminished ovarian reserve, and should not be performed upon women who desire childbearing [1]. Evidence cited for this claim was diminished AMH levels in women who underwent UAE. However, as the author of the paper noted, with a mean age of 45 their 'study population was relatively old compared to the population of women who have a desire for future pregnancy' [2]. They acknowledged that results could possibly differ in a younger age group of reproductive age. We have previously published our study of 27 patients who had undergone uterine artery embolization (UAE) before the age of 40 [3]. Their ovarian function and reserve were measured by Anti-Müllerian hormone (AMH) drawn before UAE, and again an average of six months after embolization. The prior study revealed no significant decrease in AMH after UAE [3]. This follow-up study provides a larger cohort of patients, reporting both pre- and post-UAE AMH values in a larger group of patients. In addition, a subgroup of patients ($n = 32$) had AMH levels drawn multiple times up to 47 months (mean = 10.1 ± 10.7 months) after embolization. In

this group of patients, the effect of age on AMH level was assessed by regression analysis before and after UAE, which indicated that UAE did not alter the effect of aging on AMH. In addition to AMH levels, menstrual histories and follicle stimulating hormone (FSH) were examined as indicators of ovarian function. This paper examines the effect, if any, of UAE on a woman's ovarian reserve.

Material and methods

The study was conducted from January 2012 through the present at a private practice. All patients who underwent UAE before age 40 were studied. UAE was performed bilaterally by the same physician. A small incision is made in the patient's right groin to insert a catheter into the femoral artery. With x-ray guidance, polyvinyl alcohol particles (PVA) of 500 microns or larger were injected into the uterine arteries. Magnetic resonance images were taken six months post-UAE to determine devascularization and shrinkage of fibroids.

AMH levels were drawn prior to UAE, and again at various times after embolization. Patients were followed with annual AMH levels after that period. We

did not seek investigational review board permission. Anti-Müllerian hormone levels are measured routinely to determine ovarian reserve [4,5]. Eligible patients were identified by chart review. Because our previous study and historical literature have suggested that AMH levels decline with age, it was not possible to use a simple comparison of mean AMH values pre- and several months post-procedure (e.g., a paired-t test) to unequivocally test the hypothesis that AMH is reduced by uterine artery embolization, as it is confounded by the passage of time. Instead, we compared the regression line descriptors between the regression line for the control AMH data versus patient age taken prior to UAE and the regression line for the data obtained after UAE was performed. If either the intercept decreased or the slope of the line became more negative, one could conclude that the UAE procedure affected the AMH level negatively. Namely, AMH either dropped suddenly after UAE or it began to drop more quickly with age.

Results

To date, 89 women have been enrolled in this observational study. At the time of the control, pre-op blood draw, these patients ranged in age from 23 to 41 years (mean = 35.5 ± 3.8 years). The time to the first post-op blood draw varied widely from 1 to 927 days (mean = 190 ± 229 days). Figure 1 shows that post-UAE AMH value decreased in some patients and increased in others, but on the average decreased. A

paired-t test comparing the pre-embolization AMH value with the post-embolization value indicated that the post-op value was significantly lower (2.1 ± 2.4 ng/ml versus 2.4 ± 2.6 ng/ml, respectively; $p = .047$). However, the paired-t test does not take into account the effect of age. Given that the post-op blood draw was often taken considerably after the embolization procedure (in several cases, a few years later) and that it is known that AMH decreases with age, the post-op AMH value in this study is certainly confounded by aging. Figure 1 presents the raw AMH data for each patient plotted against the age of the patient at the pre-op and first post-op blood draws. The pre-op (red circles) and post-op (blue circles) data points for each patient are connected by a line. It is clear from Figure 1 that AMH did not decrease in all patients following uterine artery embolization. AMH decreased in 54 of 89 patients (60.7%); increased in 32 of 89 patients (36.0%); and was unchanged in 3 of 89 patients (3.4%). On average AMH decreased 0.35 ng/ml after embolization.

As Seifer has demonstrated previously [6], and we have shown concurring results [3], AMH levels tend to decrease with age. This effect is demonstrated in Figure 2 by the black line which represents the linear regression line fit to Seifer's data from a population of 17,120 women. Our concurring data are represented by the red line which is the linear regression line fit to the control AMH data from 87 patients prior to embolization treatment. Note that the figure suggests that the red and black lines are close together and

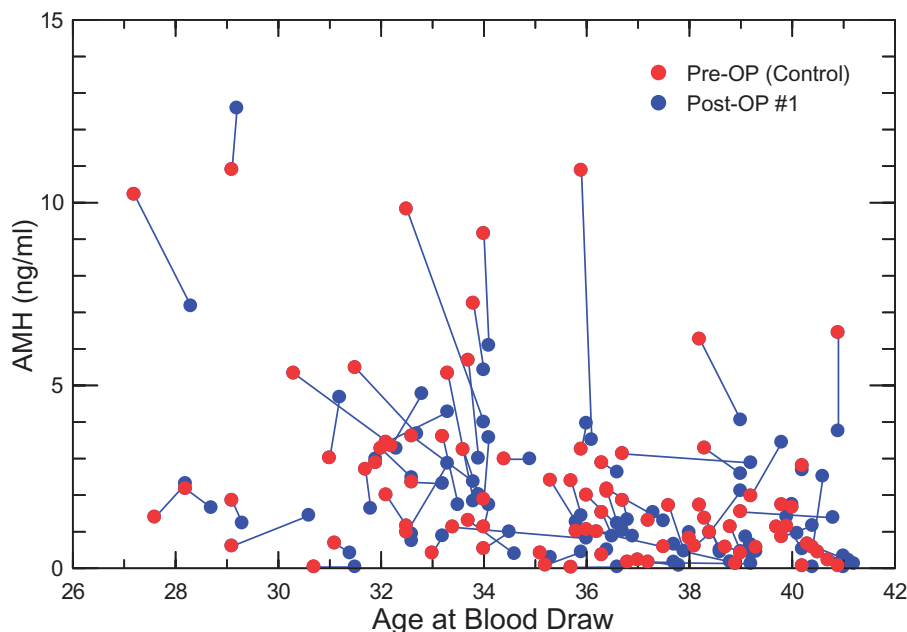


Figure 1. AMH data from pre-op (solid circle) and the first post-op (open circle) blood draws for each patient are plotted against the age of the patient at the pre-op and post-op blood draw. Data for each patient are connected by a line.

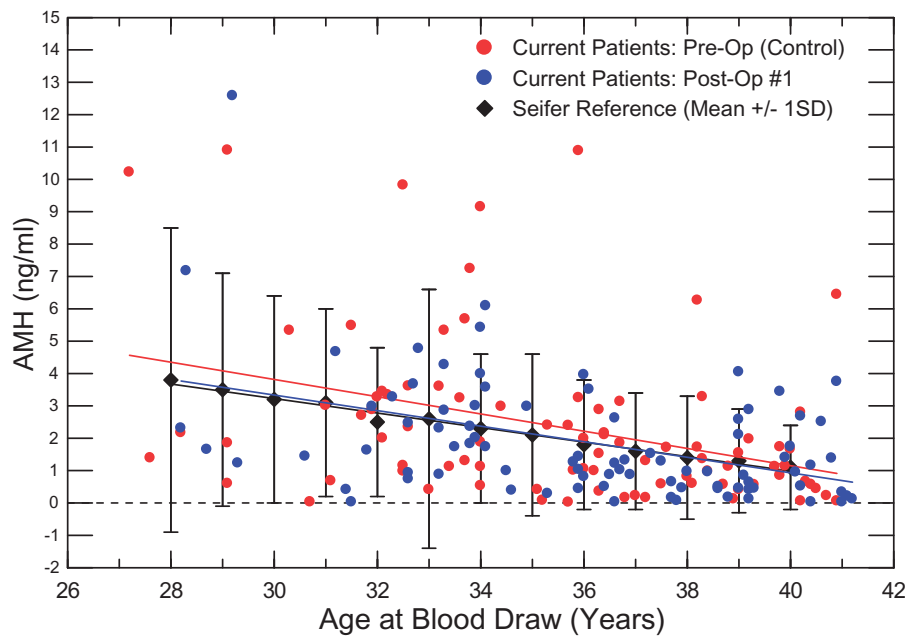


Figure 2. Results of linear regression analysis on AMH levels of 87 patients prior to uterine artery embolization (red line, solid red circles) and after embolization (blue line, solid blue circles). Data from Seifer's study including 17,120 women are overlaid in black (black diamonds showing ± 1 Std Dev) demonstrating the effect of age on AMH.

have similar slopes indicating that age affects both groups of women the same way with respect to AMH. The blue line is the linear regression line fit to the data from our 87¹ patients using the first post-op AMH values measured after embolization. There is no significant difference between the slopes of the red and blue lines (p values=0.78), which suggests that even after embolization, age has a similar effect on AMH. In addition, the proximity of the blue line to the red line suggests that, once the effect of age is accounted for, uterine artery embolization has little impact on AMH levels. This is assessed by comparing the intercept of the red and blue regression lines. The result is not significant (p values=0.70). Thus, when age is taken into account, there is no significant difference between pre- and post-op AMH values.

Finally, we assessed a subset of the current patients who had multiple follow-up measurements of AMH after UAE ($n=32$). As exhibited in Figure 3, we performed regression analysis on their pre-op control data and separately on their combined follow-up data to determine whether UAE had a deleterious long-term effect on AMH. If a long-term deleterious effect were present, one would expect the regression line for the follow-up AMH data to fall more rapidly than the line for the pre-UAE control data. Although the regression line for the post-op AMH data is below the line for the control data, the difference is not significant (p values=0.66). Moreover, the slopes of the lines are not significantly different (p values=0.73).

suggesting that UAE has not altered the effect of aging on AMH level.

Discussion

Some studies suggest that uterine artery embolization conflicts with fertility [7,8]. Prior studies listing the main reason as decrease in ovarian function post-UAE [2,9]. However, recent studies demonstrate that UAE has no negative effects on fertility and is actually a feasible option for women seeking pregnancy [10–13].

Studies performed as early as 1998 have suggested that UAE is associated with the onset of premature menopause [14]. However, these studies focused on women <40 years of age, at which time there is natural decline in ovarian function [15]. One study utilized Doppler transvaginal ultrasound to examine blood flow to the ovaries immediately before and after UAE [16]. Identical studies were then performed several months following the procedure (range 18–42 weeks; mean, 28). The majority of patients showed reestablished ovarian arterial perfusion at follow-up. The only patient that became menopausal was <40 years old. With age, a woman's reproductive vascular system becomes increasingly fragile and is less likely to resist transient disruption of flow.

In comparison with patients who have undergone abdominal hysterectomy, UAE has a lower incidence of premature menopause [13,17]. Extensive search of

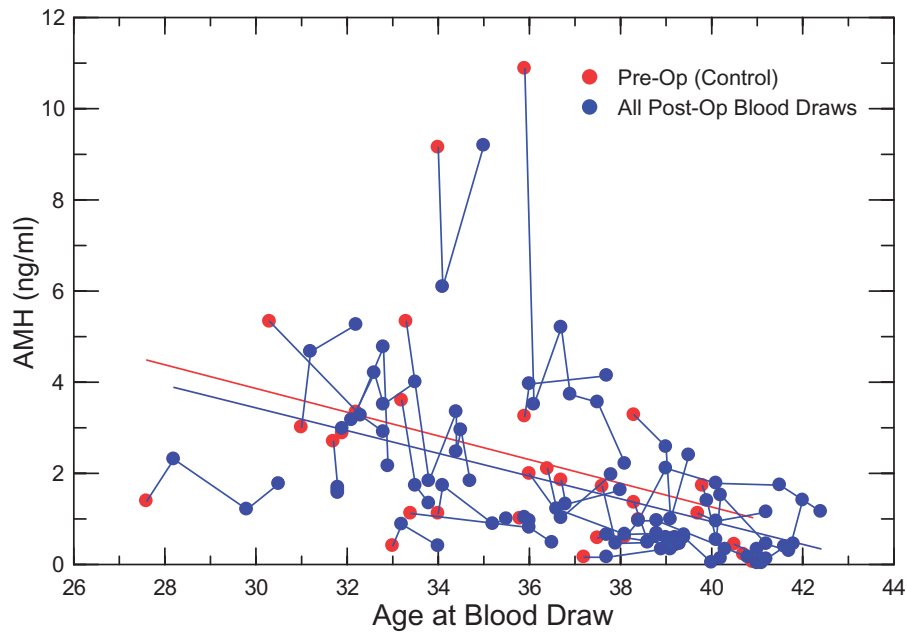


Figure 3. Results of regression analysis of pre-op control and post-op AMH data in a subset of current patients having multiple blood draws after the initial UAE procedure. Data from individual patients are connected by lines.

medical databases reveals no data on premature menopause associated with MRI-guided ultrasound therapy, although high intensity focused ultrasound (HiFu) therapy is known to cause ovarian destruction and consequent premature menopause [18]. No data were found concerning the incidence of premature menopause following myomectomy, whether abdominal or laparoscopic. In the age group observed in our study there are neither significant drops of AMH levels nor significant increases of FSH reaching menopausal levels. In fact, 48% of UAE patients ≤ 40 years old who desired fertility achieved term pregnancy [19].

Some authors have explored the etiology of UAE-related ovarian failure. One such study examined the cross-connection between the uterine and ovarian arteries in the context of embolization. As the distal portion of the ascending uterine artery terminates, it forms anastomoses with the distal ovarian artery. The study argues that during a UAE procedure, the ovarian arteries are subject to embolization intended exclusively for the uterine arteries through these anastomosing vessels, thereby compromising blood flow to the ovaries [20]. However, in patients who underwent hysterectomy with the removal of ovaries following UAE, a common finding was embolic particles in the ovarian blood supply [15].

As noted above, we found no gross increase in FSH levels, in patients < 40 . Anti-Müllerian Hormone is a good predictor of long-term ovarian reserve.

We studied our population of women of childbearing age for changes, if any, in AMH levels before and

after UAE. Regression analysis was used over other possible statistical models because it accounted for the natural decline of AMH over time. This study demonstrated that the AMH levels before and after UAE were not significantly different (p values = 0.58) in women under the age of 40. Our larger sample size of this study is consistent with both Seifer's data [6] and our earlier study [3], indicating that the pre-op and post-op AMH of UAE patients do not differ from those of women who have never had the procedure.

However, AMH levels are only one factor in predicting fertility after UAE. Follicle stimulating hormone levels were also analyzed and found not to change in our earlier publication [3]. We will publish FSH results in the larger population separately. Indeed, no patient in our study population underwent premature menopause. We have reviewed the success of our patients who wished to become pregnant. Forty-eight per cent of our population < 40 years old became pregnant. Most carried to term, and delivered healthy infants [21]. Several patients reported vaginal deliveries [11,12]. Furthermore, we have noted that the results of symptom relief and shrinkage in the younger population are durable, and similar to those found in women approaching the menopause [22].

Conclusions

Studies of AMH levels in our younger population revealed no significant effect by UAE. Longer-term regression analysis revealed only age to be a

significant factor in declining ovarian function. Combining this information with the success of patients carrying pregnancies to term following UAE suggests a reexamination of UAE in the younger population.

Acknowledgements

We acknowledge with gratitude the assistance of Jasmine Jordan, Arezu Hashemi, and Erika Moxley for research contributions.

Declaration of interest

The authors report no conflicts of interest. The authors alone are responsible for the content and writing of the papers.

Note

1. Two of the current patients were determined to be outliers and were excluded from this analysis: (1) a 23 y.o. with extremely low AMH and (2) a patient who was nearly 43 y.o. at follow-up with unusually high AMH.

References

- [1] Tulandi T, Sammour A, Valenti D, et al. Ovarian reserve after uterine artery embolization for leiomyomata. *Fertil Steril*. 2002;78:197–198.
- [2] Hehenkamp WJ, Volkers NA, Broekmans FJ, et al. Loss of ovarian reserve after uterine artery embolization: a randomized comparison with hysterectomy. *Hum Reprod*. 2007;22:1996–2005.
- [3] McLucas B, Voorhees WD III, Chua KJC. Anti-Müllerian hormone levels before and after uterine artery embolization: a preliminary report. *Minim Invasive Ther Allied Technol*. 2015;24:242–245.
- [4] Broekmans FJ, Visser JA, Laven JS, et al. Anti-Müllerian hormone and ovarian dysfunction. *Trends Endocrinol Metab*. 2008;19:340–347.
- [5] de Vet A, Laven JSE, de Jong FH, et al. Anti-Müllerian hormone serum levels: a putative marker for ovarian aging. *Fertil Steril*. 2002;77:357–362.
- [6] Seifer DB, Baker VL, Leader B. Age-specific serum Anti-Müllerian hormone values for 17,120 women presenting to fertility centers within the United States. *Fertil Steril*. 2011;95:747–750.
- [7] Goldberg J, Pereira L, Berghella V. Pregnancy after uterine artery embolization. *Obstet Gynecol*. 2002;100:869–872.

- [8] Goodwin SC, Spies JB. Uterine fibroid embolization. *N Engl J Med*. 2009;361:690–697.
- [9] Kim HS, Tsai J, Lee JM, et al. Effects of utero-ovarian anastomoses on basal follicle-stimulating hormone level change after uterine artery embolization with tris-acryl gelatin microspheres. *J Vasc Interv Radiol*. 2006;17:965–971.
- [10] Kaump GR, Spies JB. The impact of uterine artery embolization on ovarian function. *J Vasc Interv Radiol*. 2013;24:459–467.
- [11] Firouznia K, Ghanaati H, Sanaai M, et al. Pregnancy after uterine artery embolization for symptomatic fibroids: a series of 15 pregnancies. *AJR Am J Roentgenol*. 2009;192:1588–1592.
- [12] Pron G, Mocarski E, Bennett J, et al. Pregnancy after uterine artery embolization for leiomyomata: the Ontario multicenter trial. *Obstet Gynecol*. 2005;105:67–76.
- [13] Rashid S, Khaund A, Murray LS, et al. The effects of uterine artery embolization and surgical treatment on ovarian function in women with uterine fibroids. *BJOG*. 2010;117:985–989.
- [14] Reidy JF, Bradley EA. Uterine artery embolization for fibroid disease. *Cardiovasc Intervent Radiol*. 1998;21:357–360.
- [15] Chrisman HB, Saker MB, Ryu RK, et al. The impact of uterine fibroid embolization on resumption of menses and ovarian function. *J Vasc Interv Radiol*. 2000;11:699–703.
- [16] Ryu RK, Siddiqi A, Omary RA, et al. Sonography of delayed effects of uterine artery embolization on ovarian arterial perfusion and function. *Am J Roentgenol*. 2003;181:89–92.
- [17] Siddle N, Sarrel P, Whitehead M. The effect of hysterectomy on the age at ovarian failure: identification of a subgroup of women with premature loss of ovarian function and literature review. *Fertil Steril*. 1987;47:94–100.
- [18] Bohlmann MK, Hoellen F, Hunold P, et al. High-intensity focused ultrasound ablation of uterine fibroids: potential impact on fertility and pregnancy outcome. *Geburtshilfe Und Frauenheilkunde*. 2014;74:139–145.
- [19] McLucas B. Pregnancy following uterine artery embolization: an update. *Minim Invasive Ther Allied Technol*. 2012;22:39–44.
- [20] Ryu RK, Chrisman HB, Omary RA, et al. The vascular impact of uterine artery embolization: prospective sonographic assessment of ovarian arterial circulation. *J Vasc Interv Radiol*. 2001;12:1071–1074.
- [21] McLucas B, Voorhees WD III, Elliott S. Fertility after uterine artery embolization: a review. *Minim Invasive Ther Allied Technol*. 2015;25:1–7.
- [22] McLucas B, Voorhees WD III. Results of UAE in women under 40 years of age. *Minim Invasive Ther Allied Technol*. 2014;23:179–183.